



PRESENTING CLINICAL SIGNS

DATE History: Grade IV/VI left-sided murmur. Tachypnea. Radiograph suspicious for hilar edema. Started on furosemide (3.125 mg BID) and pimobendan last night. Clinical signs improved today.

4/22/22

ECHOCARDIOGRAPHIC FINDINGS

2D, M-mode, and Doppler study.

PERFORMED BY:

Dr. Meredith Swart

INTERPRETED BY

Keith Blass, DVM,
MS, DACVIM
(Cardiology)

There is moderate left atrial dilation. The mitral valve leaflets are thickened and exhibit systolic prolapse. There is Doppler evidence of mitral regurgitation present. There is moderate left ventricular dilation. Left ventricular systolic function is hyperdynamic. The aorta and aortic valve are normal. Right atrial and right ventricular dimensions are normal. The tricuspid valve is normal. The pulmonary artery and pulmonic valve are normal. No pericardial effusion or cardiac masses are seen.

LA - 31.7 mm
LVIDd - 31.5 mm
LVIDs - 13.9 mm
FS - 55.9%
LVOT - 1.08 m/s
RVOT - 0.83 m/s

PATIENT

Bedbug Cross

ASSESSMENT/RECOMMENDATIONS

SPECIES

Degenerative mitral valve disease

Canine

This examination demonstrates regurgitation of blood across Bedbug's mitral valve resulting from degenerative valve disease. Secondary to her regurgitation, Bedbug has moderate dilation of both her left atrium and left ventricle, though her left ventricular systolic function is well-preserved.

BREED

Chihuahua Mix

Given the presence of moderate left atrial dilation, it would come as no surprise if Bedbug experienced an episode of left-sided congestive heart failure (CHF), and her improvement with cardiac therapy appears to confirm this. In addition to CHF, Bedbug is at risk for the development of exercise intolerance, syncope, and a cough, therefore, careful monitoring for these signs is recommended.

SEX

FS

Bedbug's current cardiac medications are appropriate, as is therapy with enalapril (2.5 mg am, 1.25 mg pm).

AGE

13 y

Recheck radiographs and a renal/electrolyte profile are recommended in 1 week. A recheck echocardiogram is recommended in 6-9 months.

WEIGHT

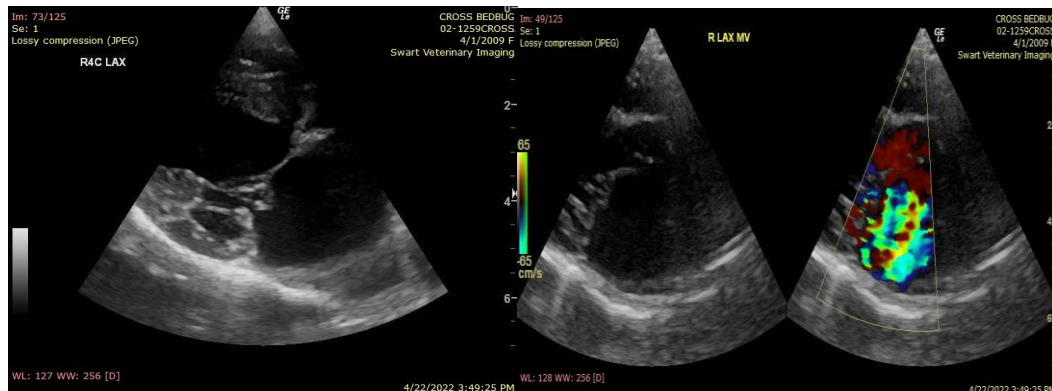
8 lb

HOSPITAL NAME

Swart Veterinary
Imaging

REFERRING VET

Dr. Swart





DATE

4/22/22

The information and recommendations provided are based on the images presented by the referring veterinarian. No evaluation can be communicated regarding pathology that was not visible in the image/video clips provided.

Thank you for this referral. If the clinical or image interpretation does not parallel your findings or if I can be of any further assistance please contact me.

PERFORMED BY:

Dr. Meredith Swart

Keith Blass, DVM, MS, DACVIM (Cardiology)
KeithBlass@gmail.com
631-804-5754

INTERPRETED BY

Keith Blass, DVM,
MS, DACVIM
(Cardiology)

PATIENT

Bedbug Cross

SPECIES

Canine

BREED

Chihuahua Mix

SEX

FS

AGE

13 y

WEIGHT

8 lb

HOSPITAL NAME

Swart Veterinary
Imaging

REFERRING VET

Dr. Swart